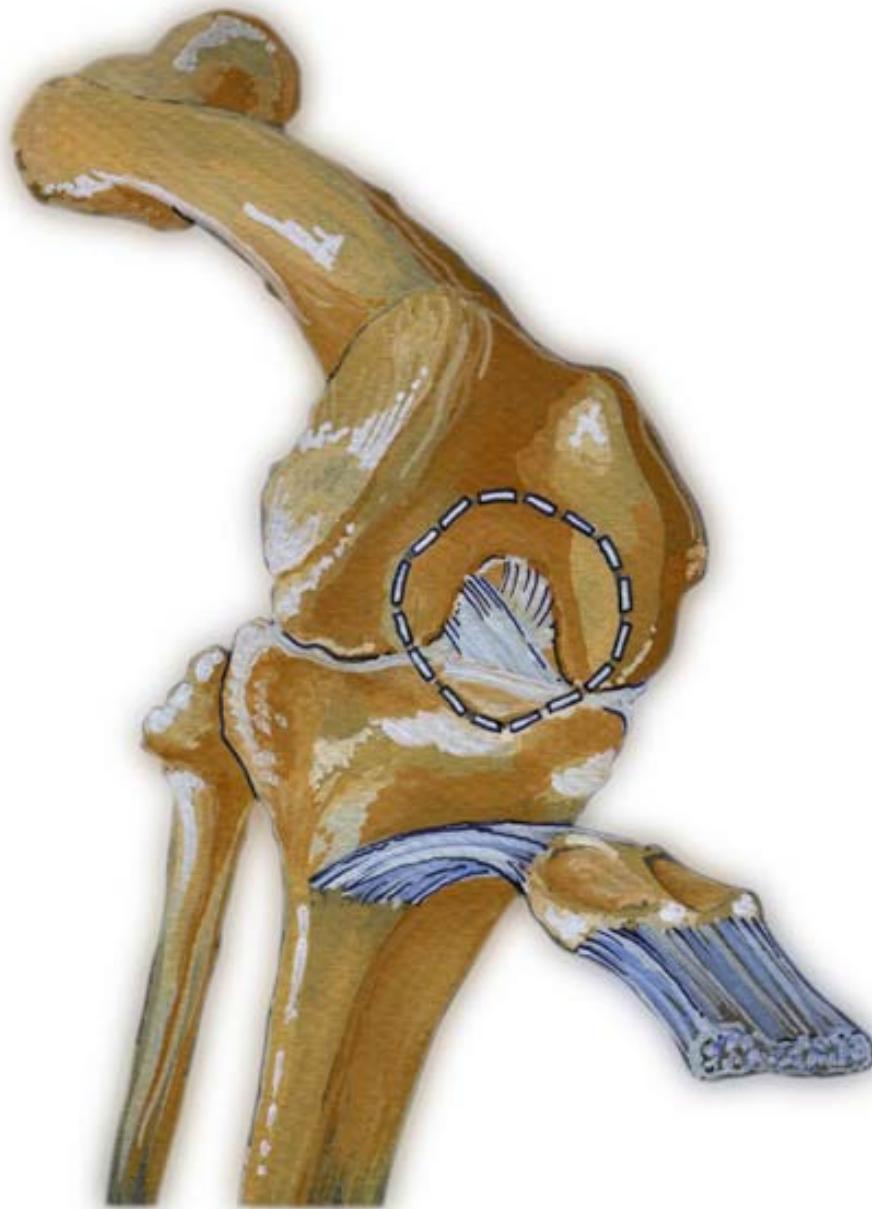

# Common Foot Pathologies



Chondromalacia Patella  
(patellofemoral pain syndrome)

# Chondromalacia Patella

## (patellofemoral pain syndrome)

### What is it?

Chondromalacia (of Greek origin meaning "softening of the cartilage") is a degenerative cartilage condition wherein the cartilage on the back of the patella (knee cap) is irritated and painful because it rubs against the medial femoral condyle.

### What are the common symptoms/complaints?

Patients complain of dull, aching pain leading to sharp localized pain in the front of the knee, particularly while going up or down stairs and hills. They may feel a grinding sensation and stiffness when squatting, bending and climbing stairs. The patient may experience the sensation of the knee "giving away" beneath them.

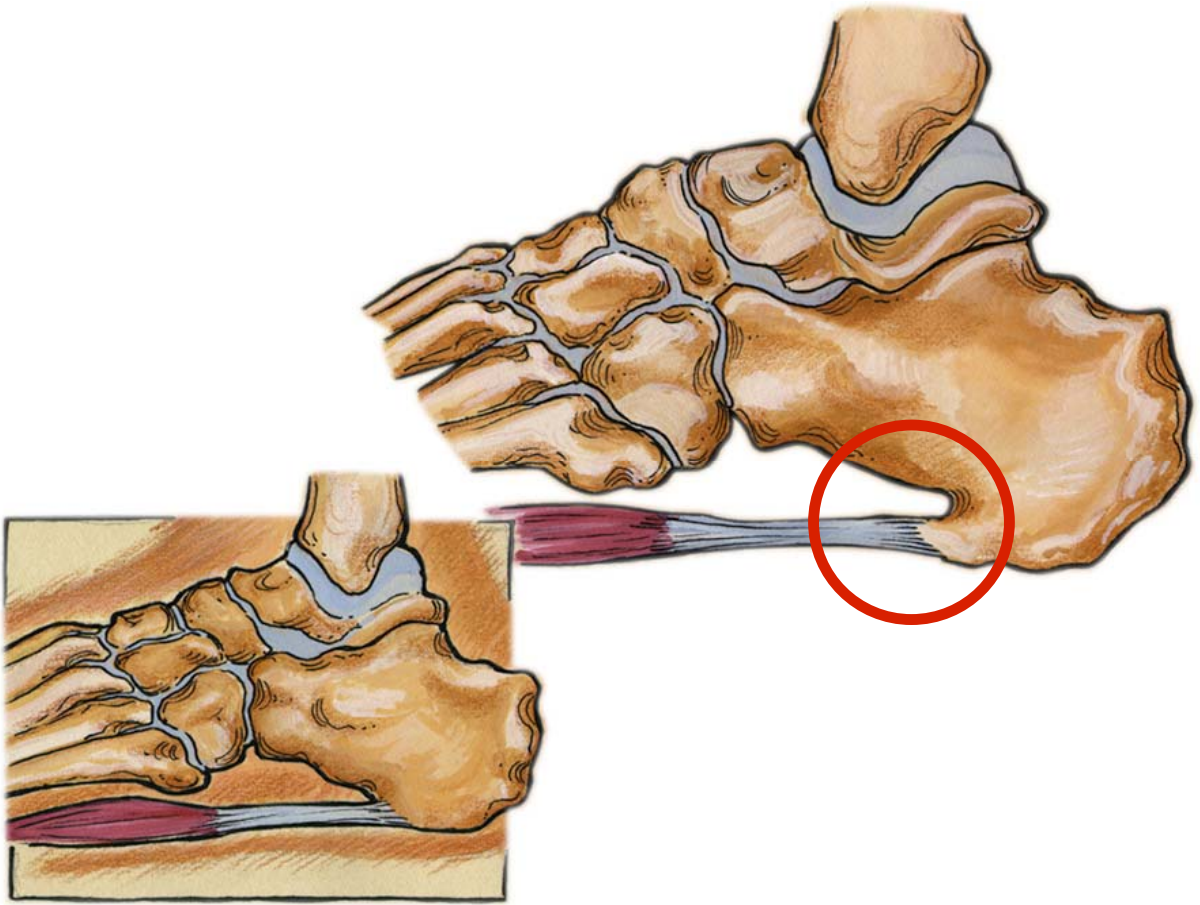
### How is it caused?

During normal walking, the femur (thigh) and the tibia (lower leg) rotate in unison. An abnormal walking pattern (over-pronation) may cause the thigh and lower leg to rotate out of sync causing misalignment of the lower extremity. The resulting counter rotation of the femur and the tibia causes the patella to rub against the medial femoral condyle instead of moving smoothly up and down in its normal track, causing pain and damage to the cartilage, leading to chondromalacia.

*Note: The saddle-shaped superior surface of the talus bears the weight of the body transmitted via the tibia. Hence, over-pronation may result in the tibia internally rotating beyond the end of contact phase while the femur begins rotating externally at mid-stance.*

### How is it treated?

Treatment options vary according to symptoms and the severity of the injury. The patient may respond well to quadriceps strengthening exercises and a hamstring flexibility program. Actions such as crouching, knee bends and resistance exercises with knee extension from a fully flexed position should be avoided. Most importantly, proper alignment of the patella must be maintained. Once over-pronation has been arrested, and alignment regained, healing can begin. The patient should be fitted with orthotics and will likely experience pain relief within weeks and complete recovery within months (generally 2 - 3 months).



Plantar Fasciitis (Heel Spur Syndrome)

# Plantar Fasciitis (Heel Spur Syndrome)

## What is it?

Plantar fasciitis is a condition wherein the plantar fascia is pulling on the periosteum at the calcaneus therefore causing inflammation and pain.

The plantar fascia is connective tissue that acts as a stabilizer and maintains the integrity of the arch of the foot. It originates at the plantar aspect of the calcaneus and is attached to the metatarsal heads and continues forward to insert on the proximal phalanges as well as forming the fibrous flexor sheath in each toe.

## What are the common symptoms/complaints?

Patients complain of severe pain felt in the heel at the hindfoot (plantar surface of the calcaneus) particularly when they take their first few steps of the day, or after they have been off their feet for a prolonged period of time. Pain after rest!

## How is it caused?


The plantar fascia is repeatedly over-torqued because the calcaneus in the hindfoot is stable while the forefoot is over-pronating. This shearing force causes the plantar fascia to become inflamed. Because the weakest part of the plantar fascia is the attachment to the periosteum (fibrous membrane covering the bone) at the calcaneus, pain on the medial side of the calcaneus is felt. When the plantar fascia is repeatedly twisted, it pulls the periosteum away from the calcaneus and causes the pain and inflammation. If this happens often enough, the calcaneus will eventually grow toward the plantar fascia in an effort to re-attach itself. That bone growth is called a **heel spur**.

The pain is felt during the first few steps of the day because during the night, the fibres of the fascia try to heal themselves by forming fragile new fibre, and when the person puts weight on the foot, renewed tearing takes place and the pain becomes severe.

## How is it treated?

Treatment options vary according to symptoms. If the pain is caused by over-pronation and continuous torquing of the fascia, an aggressive more rigid orthotic is needed to arrest the torquing and stabilize the forefoot. If the pain is found in the middle area of the plantar fascia, aggressive rearfoot control is needed and can be found with orthotics. Since the problem is the over-pronation, orthotics that control pronation and arch elongation should be prescribed. The patient can expect a 20-25% improvement every 2 weeks until complete recovery, which generally takes 2 to 3 months.





Achilles Tendonitis

# Achilles Tendonitis

("Achilles" from Greek mythology)

## What is it?

Achilles tendonitis is a condition wherein the achilles tendon, at or near its insertion to the posterior aspect of the calcaneus, becomes inflamed and causes pain.

The achilles tendon is one of the longest and strongest tendons in the body. It is avascular and therefore slow to heal. The Achilles Tendon is formed in the lower third of the posterior aspect of the tibia. Two muscles join to form the Achilles tendon: the Gastrocnemius which originates on the posterior aspect of the femur, and the Soleus which originates on the posterior aspect of the upper third of the tibia. The Achilles tendon works as an anti-pronator.

## What are the common symptoms/complaints?

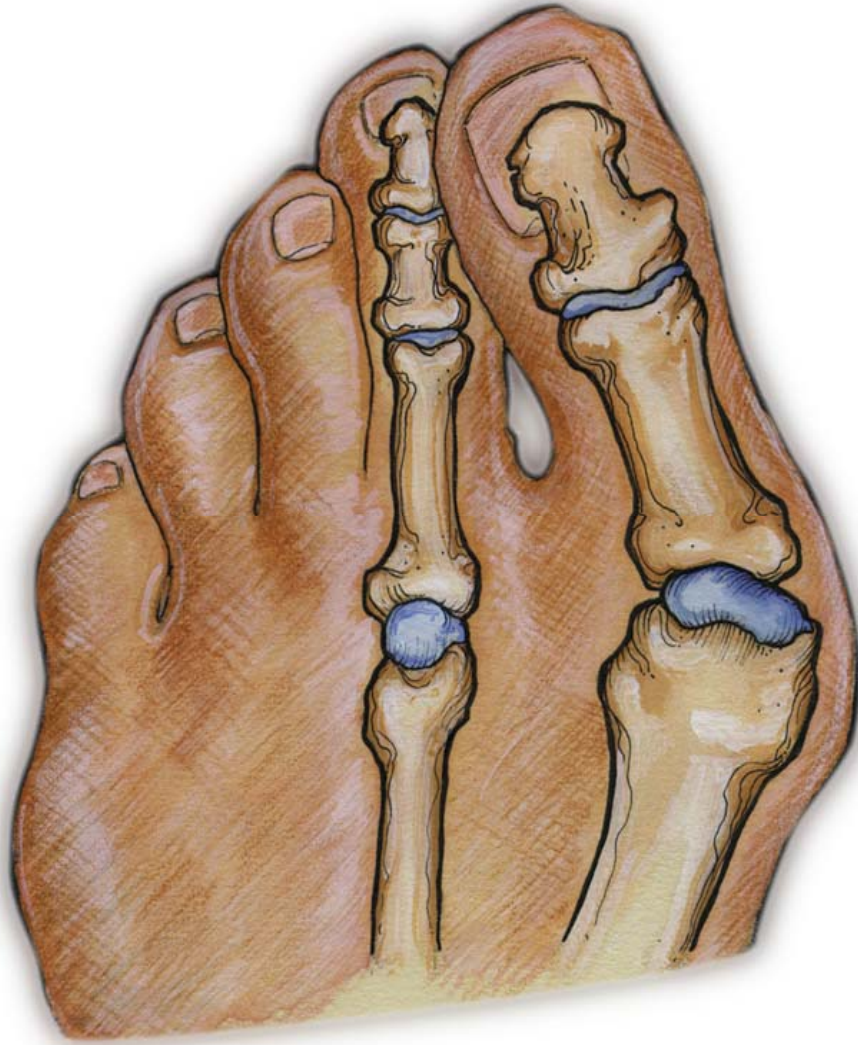Patients complain of severe aching or burning pain felt in the back of the heel, which increases with passive dorsiflexion and resisted plantarflexion, such as rising up onto the toes.

## How is it caused?

Over-pronation, overstress of the tendon. Risk factors include tight heel cords, foot malalignment deformities, recent change in activities or shoes. During a normal gait cycle, the femur and the tibia rotate in unison (i.e. internally during pronation and externally during supination). However, when a person over-pronates, the tibia is locked into the talus by the saddle joint and therefore continues to rotate internally past the end of the contact phase while the femur begins to rotate externally at the beginning of midstance. The Gastrocnemius muscle is attached to the femur and rotates externally while the Soleus muscle is attached to the tibia and fibula and rotates internally during pronation. The resulting counter rotation of the femur and the tibia causes a shearing force to occur in the Achilles tendon. This counter rotation twists the tendon at its weakest area, namely the Achilles tendon itself, and causes the inflammation. Since the tendon is avascular, once inflammation sets in, it tends to be chronic.

## How is it treated?

Relieving the stress is the first course of action. Acute treatment involves ice therapy and activity modification. Active stretching and strengthening exercises will assist rehabilitation of the gastrocnemius-soleus complex. When placed in a heeled shoe, the patient will immediately notice a difference, compared to flat ground. It is recommended that the patient be fitted with orthotics to control the down and in movement of the talus and maintain proper alignment, relieving the stress on the achilles tendon. Tightness in the tendon itself can be helped by an extra heel lift added to the orthotics. The patient can expect a slow recovery over a period of months.



Bunion



# Bunion

(*"Hallux Valgus"*)

## What is it?

A bunion is a medial deviation and inflammation of the metatarsophalangeal (MTP) joint of the big toe. The capsule of the joint is subluxed (displaced), thickened and enlarged, and the cartilage of the joint is damaged. There are three degrees of bunions: mild, moderate and severe.

Bunions are not hereditary, although the tendency to over-pronate, which is the cause of bunions, has a hereditary component.

## What are the common symptoms/complaints?

Patients complain of pain in the MTP joint and have a deformed (medially deviated) big toe. Often, they are only able to wear very wide shoes.

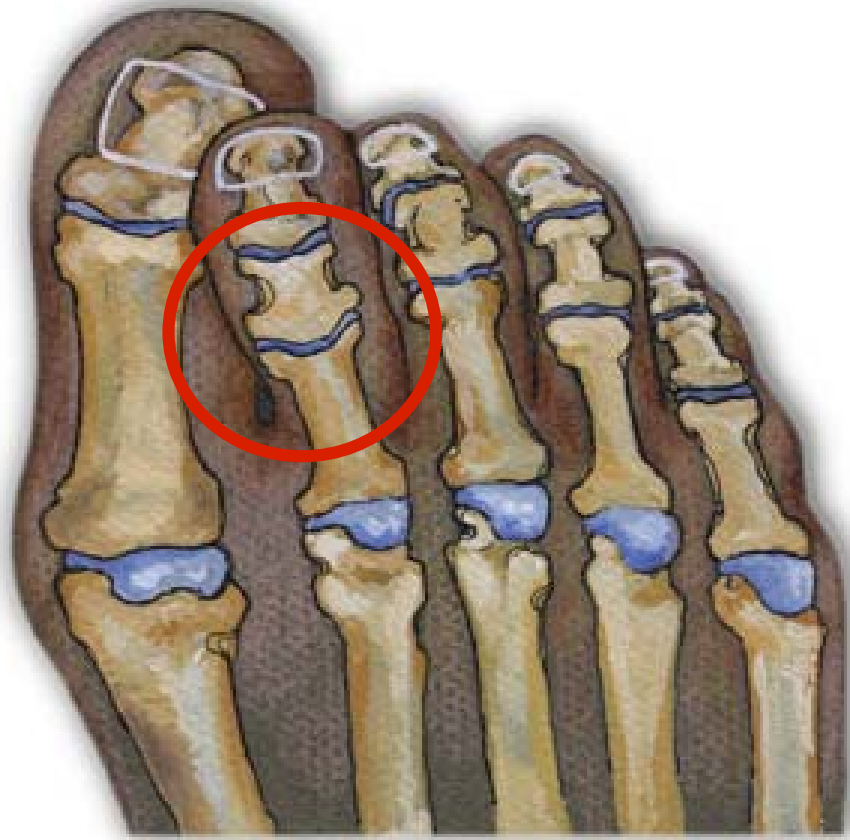## How is it caused?

Prolonged pressure against the medial aspect of the first MTP joint can lead to thickening of the medial capsule and bursa, resulting in severe valgus deformity of the great toe. Normally "toe-off" occurs from the plantar surface of the big toe. Over-pronation can cause the propulsion phase of stance to take off from the medial aspect of the phalanges of the big toe instead of the plantar surface. As a result, there is a retrograde force into the joint which pushes it out medially and stretches the joint capsule. This tearing and stretching of the joint capsule as well as the wear and tear on the cartilage causes the pain.

## How is it treated?

Since the problem is the over-pronation, the patient should be fitted with orthotics and can expect a slow recovery over a period of months. Orthotics will not cause the physical deformity to regress, but will simply arrest any further progression and likely stop the pain.

It is important to note however, that when bunions are severe and require surgery, the bunion can be corrected, but will develop again unless the root cause of over-pronation is corrected. Since over-pronation is the root cause, orthotics are still necessary.



Hammer Toes

# Hammer Toes

## What is it?

Hammer toes is a condition wherein there is contracture of the proximal interphalangeal joint (usually in the second toe, but sometimes the third toe). It is extended at the metatarsophalangeal (MTP) joint, flexed at the proximal interphalangeal joint, and extended at the distal interphalangeal joint.

## What are the common symptoms/complaints?

Patients may feel pressure against the shoe and under the metatarsal head, particularly the second toe, which is often caused by the retrograde pressure on the big toe. Patients complain of pain felt on the dorsal aspect at the PIP joint of the hammer toe itself usually due to a corn/callus that has developed. Once this happens, it is painful to wear regular shoes.

## How is it caused?

A Hammer Toe may be caused by improperly fitted shoes or a dropped metatarsal head which presses on the flexor tendon (flexor complex - the group of muscles running on the plantar surface of the toes). This pressure causes the proximal phalanx to remain dorsiflexed, and the toe becomes "hammered." Some other causes are diabetes, arthritis, neuromuscular disease, polio or trauma.

## How is it treated?

First push up on the plantar surface of the metatarsal head and see if the toe straightens out. If it does, then an orthotic could correct the problem, usually with a metatarsal pad. If the toe does not straighten out when the metatarsal head is pushed up, then that indicates that contracture in the capsule and ligaments (capsule contracts because the joint was in the wrong position for too long) of the MTP joint has set in and surgery is required. Orthotics are required post-surgically.



Posterior view of right leg and foot

# Shin Splints

Medial = tibialis posterior

Anterior = tibialis anterior

## What is it?

**Medial shin splints** are a condition wherein the periosteum of the tibia is damaged when it is pulled away by an overstressed tibialis posterior muscle.

**Anterior shin splints** are a condition wherein the blood flow is obstructed from the anterior compartment due to the hypertrophy of the overstressed tibialis anterior compartment.

## What are the common symptoms/complaints?

**Medial shin splints:** Patients complain of a dull, aching pain felt along the medial side of the tibia. Once it starts, any activity will aggravate it.

**Anterior shin splints:** Patients complain of dull, aching pain felt along the anterior side of the tibia. This can be a medical emergency due to lack of blood flow leading to neurosis and gangrene of muscle in the anterior compartment.

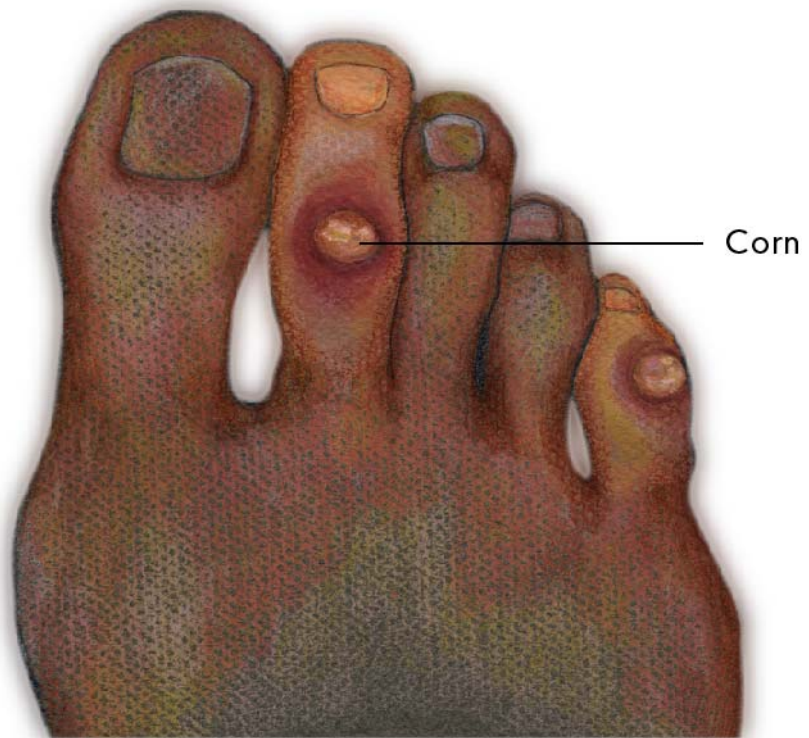## How is it caused?

**Medial shin splints:** The tibialis posterior muscle plantarflexes and inverts the foot (anti-pronator) due to its distal attachment (insertion) on the medial aspect of the foot. During over-pronation the tendon of the tibialis posterior is stretched and pulled upon excessively, thereby attacking the weakest area, namely its origin (proximal attachment) on the periosteum of the tibia. The small pain fibres of the periosteum are torn away causing pain and chronic inflammation.

**Anterior shin splints:** The tibialis anterior muscle dorsiflexes and inverts the foot, acting as an anti-pronator due to its distal attachment (insertion) on the medial aspect and base of the first metatarsal. During over-pronation the tibialis anterior muscle fibres must fire constantly to oppose (re-supinate) the over-pronation, thus causing hypertrophy (swelling) of the tibialis anterior compartment. With the anterior compartment being tightly constricted, the swollen tibialis anterior can cause an obstruction of blood flow, which, in turn can cause severe pain due to **ischemia** (lack of oxygen). This can be very serious, and may require emergency surgery. An example of Ischemia is angina.

## How is it treated?

**Medial and anterior shin splints:** Depending on the severity of the injury, treatment may include standard acute care, restricted activity and an orthotic device that corrects the over-pronation and stops the foot from falling too far medially (reducing the strain on the tibialis posterior) and facilitates proper foot function and timing, reducing the stress on the tibialis anterior.



Corns

# Corns

(from the Latin *cornu* meaning "horn")

## What is it?

A corn (heloma) is an area of thickened skin tissue on the top of the toes (due to shoe irritation) or in between the toes due to irritation and friction (usually 2nd metatarsal) from a bony prominence.

## What are the common symptoms/complaints?

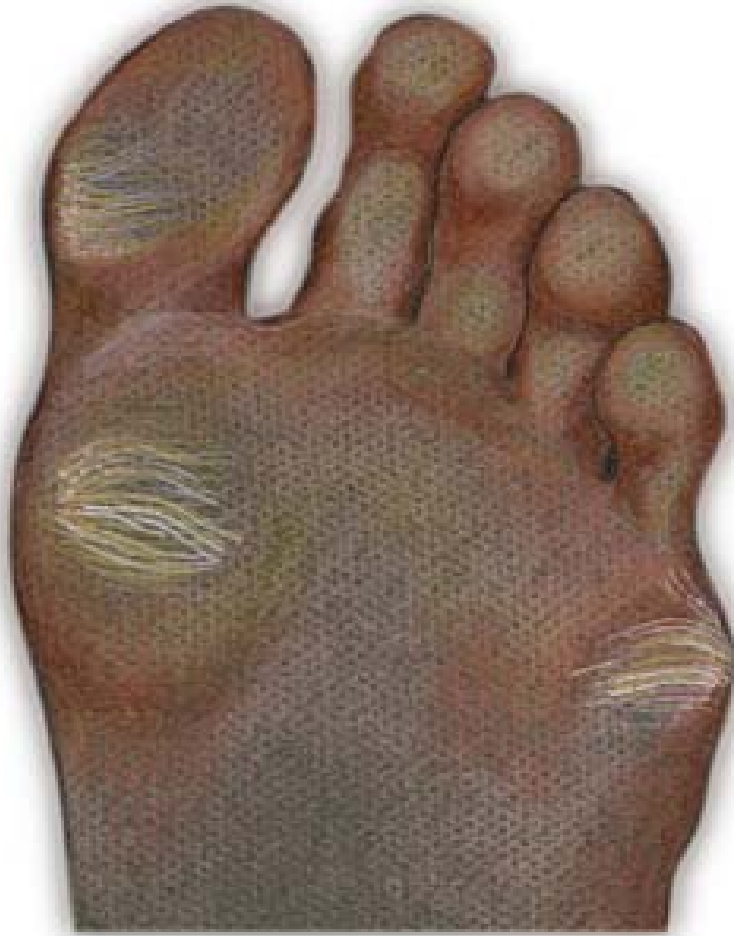Patients will complain of pain at the site of the corn. Soft corns at the webspace may become infected.

## How is it caused?

Corns are caused or aggravated by abnormal friction (instability or over-pronation) occurring between a bony prominence and also because pronation causes the foot to function like a "loose bag of bones". The result is hypermobility of the foot, causing the bony prominences to irritate and break down the soft tissue between the toes. When the "loose bag of bones" phase goes on too long, the skin is trapped between the bony prominences in the foot and the inside of the shoe, causing friction and irritation. The skin of the foot thickens to protect itself from the irritation but then leaves even less room between itself and the inside of the shoe, resulting in pain.

## How is it treated?

Temporarily the corns can be cut away, however, since the problem is made worse by over-pronation, the patient should be fitted with an orthotic device that restricts the instability and reduces friction. The patient will likely experience comfort and relief within weeks.



Calluses



# Calluses

(Hyperkeratotic Tissue)

## What is it?

A callus is an area of thickened skin tissue on the bottom of the foot due to irritation. They are localized to high friction areas, typically under bony prominences.

## What are the common symptoms/complaints?

Patients will complain of pain at the site of the callus. They will feel maximum pain with direct pressure.

## How is it caused?

The integrity of the protective barrier the skin provides the foot is critical in maintaining weight-bearing function. Callus formation occurs in areas of high vertical and shear loads and defends against blistering and ulceration. However, this process itself can cause symptoms and predispose patients with poly-neuropathy to deep infection. Even when considering a 'healthy' foot, poor foot function can lead to callus formation. During over-pronation, the foot rolls across the metatarsal heads -- one at a time -- instead of distributing the weight equally. This happens because the foot is a "loose bag of bones" during pronation causing hypermobility of soft tissues. When the "loose bag of bones" phase goes on too long and the skin is trapped between the bones in the foot and the ground, the friction of individual metatarsal heads bearing all the weight can cause inflammation. The skin thickens in the inflamed area to protect the sore spot. This thick build up of skin so close to the nerve endings in the bottom of the foot is what causes the pain.

## How is it treated?

Soft tissue care and maintenance is recommended. However, since the problem is high vertical and shear loading the patient should be fitted with orthotics to properly redistribute plantar pressures. Within weeks, the patient will likely feel pain relief. The calluses can be cut away or will eventually go away on their own once the irritation no longer exists.



## Morton's Neuroma

# Morton's Neuroma

## What is it?

Morton's neuroma is characterized by pain located in the third interspace. The next most common locations are the second, fourth and first interspaces.

## What are the common symptoms/complaints?

A burning sensation is present in the interspace and typically radiates to the adjacent digits. Patients will complain of numbness, a 'pins and needles' type of tingling and loss of sensation in the corresponding toes.

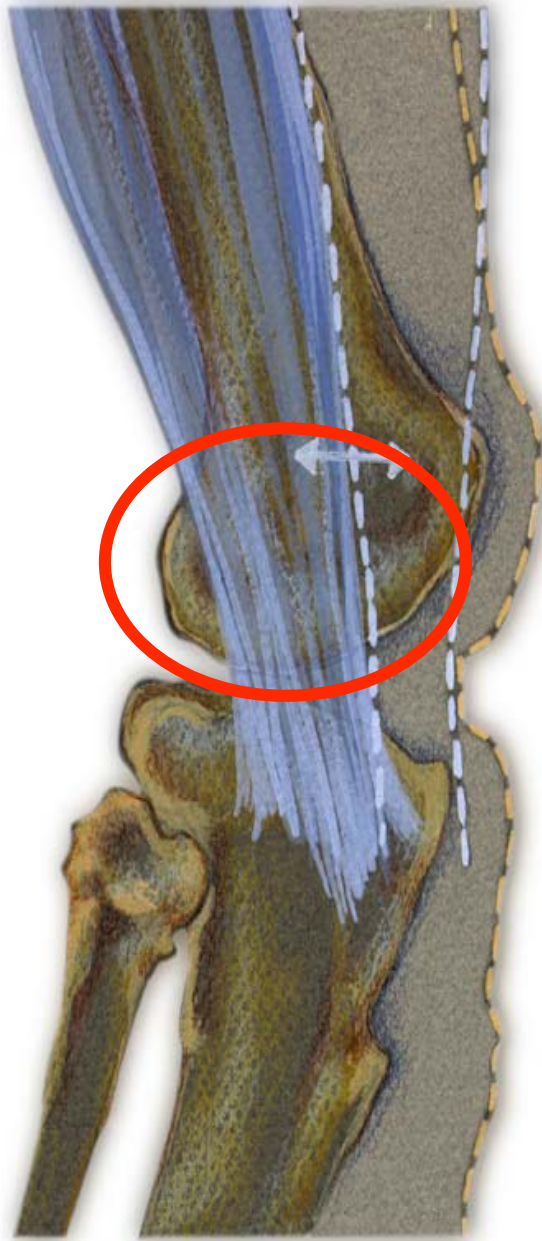
## How is it caused?

During certain kinds of over-pronation, a pivoting on the 3rd and 4th metatarsals can cause a shearing force. This shearing force between the 3rd and 4th metatarsals entraps the digital nerve and causes inflammation. The inflammation is what causes the pain.

In cases of abnormal subtalar and midtarsal joint pronation, there is excessive transverse plane movement of the metatarsals. Since the 1st, 2nd and 3rd metatarsals articulate with the cuneiforms and act as one functional unit, and the 4th and 5th metatarsals articulate with the cuboid and act as another, there can be significant motion between the 3rd and 4th metatarsals which can cause an irritation to the nerve that runs between them. This inflammation causes the pain.

## How is it treated?

Pain can be momentarily relieved by massaging the affected interspace. Control of the abnormal transverse plane motion of the foot is successful in reducing the symptoms associated with a neuroma. Orthotics should be prescribed, as they will diminish excessive transverse plane rotation between the medial and lateral columns of the foot, reducing pain and inflammation caused by Morton's neuroma. In instances where the symptoms are non-responsive, a neuroma pad should be added as accommodation to assist in diminishing transverse plane metatarsal movement and compression. Neuromas present in additional interspaces can be successfully treated with functional foot orthotics used to control abnormal foot function in the propulsive phase of gait. The patient will likely experience some pain relief within weeks and complete recovery within months (generally 2 - 3 months, but may take as long as 12 months).



**Ilio Tibial Band Syndrome**  
(a.k.a. friction syndrome)

# Ilio Tibial Band Syndrome

("friction syndrome")

## What is it?

The ilio tibial band runs from the hip to the lateral side of the proximal end of the tibia. Its function is to resist internal rotation of the tibia as well as to maintain the lateral integrity of the leg. Ilio tibial band "friction syndrome" is a condition wherein the ilio tibial band is stretched and torqued and the distal end rubs across the lateral condyle of the femur.

## What are the common symptoms/complaints?

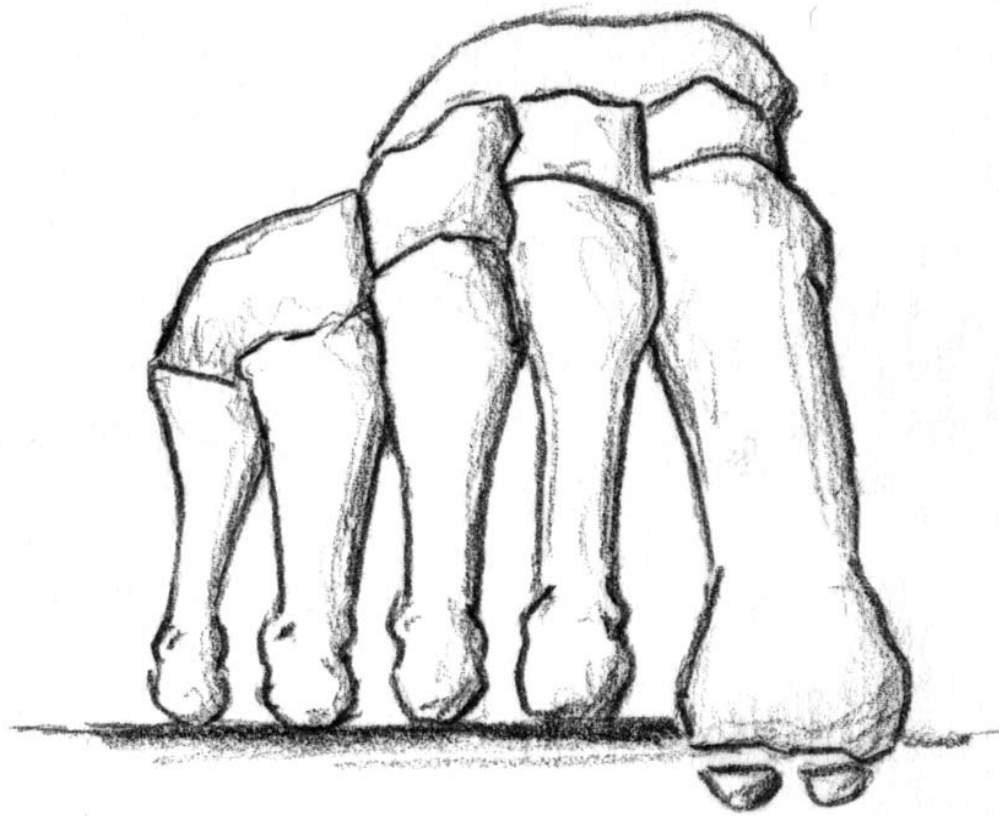
Patients complain of pain on the lateral side of the knee often extending up the lateral side of the thigh as high as the hip.

## How is it caused?

Overstress of the ilio tibial band. During a normal gait cycle, the femur and the tibia rotate in unison (i.e. internally during pronation and externally during supination); however, when a person over-pronates, the tibia is locked into the talus by the saddle joint and therefore continues to rotate internally past the end of the contact phase while the femur begins to externally rotate with the pelvis during midstance phase. The resulting counter rotation of the femur and the tibia causes a shearing force to occur in the ilio tibial band is torqued and stretched. The result is that the distal end of the band rubs across and is irritated by the lateral condyle of the femur.

## How is it treated?

Massage and stretching of surrounding muscles to help ease the tightness and ice to reduce inflammation. Since the problem is the abnormal pronation, the patient should be fitted with functional orthotics to correct the prolonged pronation thereby reducing the counter rotation between the femur and the tibia, alleviating stress off of the ilio tibial band.



Dropped Metatarsal

# Dropped Metatarsal Head

## What is it?

A dropped metatarsal head is a condition where one of the metatarsal bones (usually the second metatarsal) is lower than the others at the distal end.

## What are the common symptoms/complaints?

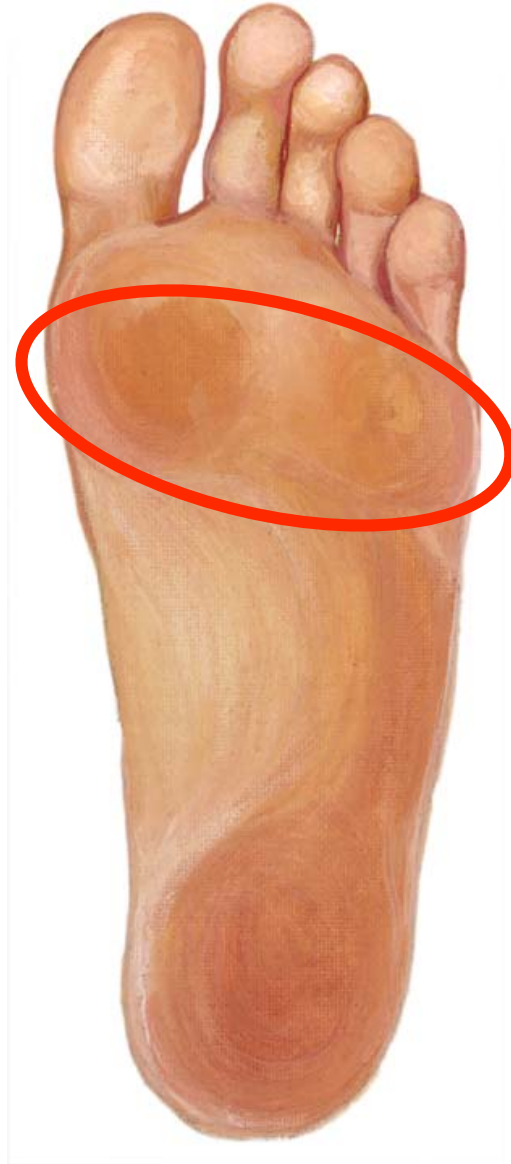Patients complain of pain and the sensation that they are walking on a stone. The patient will usually have a callus under the head of the dropped metatarsal.

## How is it caused?

This condition is very common and the cause is considered to be almost strictly hereditary. Over-pronation does play a role as abnormal weight distributions in an abnormally pronated foot tend to throw too much weight to the second metatarsal.

## How is it treated?

Orthotics should be used to redistribute the pressure and off-load the dropped metatarsal head. A metatarsal pad should be added just proximal to dropped metatarsal to off-weight it and alleviate the pain.



**Metatarsalgia**



# Metatarsalgia

## What is it?

Generalized pain underneath the metatarsals.

## What are the common symptoms/complaints?

Patients will complain of pain or tenderness on the plantar surface of the foot in the metatarsal area and/or diffused pain in the metatarsal joints.

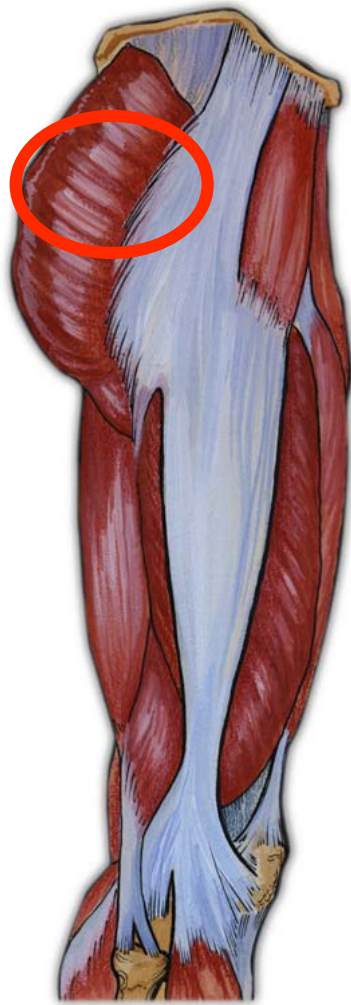## How is it caused?

This condition is very common and the cause is abnormal weight distribution due to abnormal pronation.

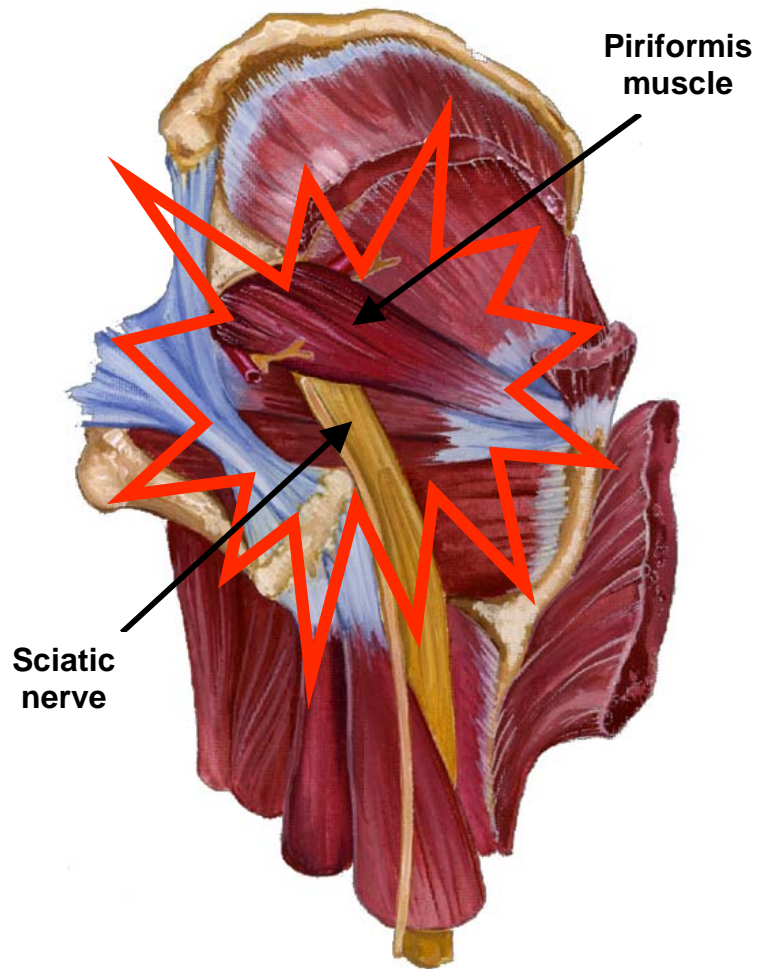
## How is it treated?

Orthotics should be worn to correct abnormal pronation and redistribute the weight more evenly along the plantar surface. If shoe fit allows, a metatarsal bar will assist by off-loading the metatarsal heads, alleviating pain localized under the metatarsal heads.

# Piriformis Syndrome



Superficial lateral view of location of the piriformis muscle



Posterior view of sciatic nerve running interior to the piriformis muscle

## Piriformis Syndrome

## **What is it?**

The piriformis muscle originates on the sacrum and crosses over at a slightly downward angle to the outside of the hip, attaching to the lateral side of the femur. Its function is to laterally rotate and extend the hip joint. Piriformis syndrome is a condition in which the piriformis muscle irritates the sciatic nerve, causing pain in the buttocks and referred pain down the leg along the path of the sciatic nerve.

## **What are the common symptoms/complaints?**

An irritating pain in the buttocks and referring pain down the leg along the path of the sciatic nerve. Pain is aggravated by sitting, squatting or walking. When relaxed, the affected leg is often externally rotated.

## **How is it caused?**

If the leg has been externally rotated for an extended period of time (i.e. driving long distances) the piriformis muscle can shorten. Continual internal rotation of the femur (result of prolonged pronation and poor foot mechanics) can cause the piriformis muscle to overwork and therefore increase in size. In both instances, when the leg tries to straighten out (i.e. walking) the involved muscle compresses the sciatic nerve.

## **How is it treated?**

Stretching of the piriformis muscle is necessary. Massage is helpful in relieving tightness. Faulty pelvic and foot mechanics need to be addressed. If internal rotation of the femur and prolonged pronation is evident, an orthotic device should be prescribed to arrest over-pronation and control the leg from internally rotating too much and too long.